

Is this TRALI, TACO, or just pneumonia? – a case report of acute respiratory failure

Michał Pluta¹, Magdalena Dziech¹, Tomasz Jaworski², Łukasz J. Krzych²

¹Students' Scientific Society, Chair of Anaesthesiology and Intensive Care, Medical University of Silesia in Katowice, Poland

²Chair and Department of Anaesthesiology and Intensive Care, Medical University of Silesia in Katowice, Poland

Dear Editor,

Blood transfusion carries some risk of complications. Transfusion-related acute lung injury (TRALI) is a rare but potentially fatal variant of acute respiratory failure (ARF), occurring as non-cardiogenic pulmonary oedema [1]. In patients with chronic circulatory failure, TRALI can co-exist with transfusion-associated circulatory overload (TACO). Moreover, TRALI should be differentiated from pneumonia [2].

CASE PRESENTATION

A 69-year-old female patient was admitted to the intensive care unit (ICU) from the emergency department (ED) due to hypovolaemic shock resulting from massive upper gastrointestinal (GI) bleeding. On admission, the patient was conscious (Glasgow Coma Scale – 15 pts), in logical verbal contact, with circulatory failure (noradrenaline – $0.23 \mu\text{g kg}^{-1} \text{min}^{-1}$). Endotracheal intubation was performed, and mechanical ventilation was initiated. Moreover, antihemorrhagic treatment (terlipressin, tranexamic acid, calcium) and haemodynamically-guided fluid resuscitation were applied. A rescue attempt was made to manage the bleeding endoscopically, which failed. CT was performed, evidencing a haemorrhaging duodenal tumour. The patient underwent emergency Whipple surgery.

In the perioperative period, the patient required numerous transfusions of blood products (7 units of red cell concentrate, 14 units of fresh frozen plasma, 1 package of platelet concentrate, 14 units of cryoprecipitate). The patient developed circulatory fail-

ure (escalation of noradrenaline to the dose of $0.91 \mu\text{g kg}^{-1} \text{min}^{-1}$) and respiratory failure (a decrease in the Horowitz index from 408 to 203).

DIFFERENTIAL DIAGNOSIS

The differential diagnosis of ARF was performed, involving the cardiogenic and non-cardiogenic causes resulting from infection (pneumonia, sepsis) and the effects of non-infective factors (aspiration of gastric content, pancreatitis, post-transfusion complications, pneumothorax, pulmonary embolism, intra-alveolar haemorrhage).

Bedside X-ray revealed massive, mottled shades located on both sides of perihilar areas (Figure 1A). Echocardiography (the FATE protocol) demonstrated a normal left ventricular systolic function and the presence of low amounts of fluid in both pleural cavities. The size of cardiac cavities was normal. Collapse of the inferior vena cava was slight. Ultrasound of the lungs (the BLUE protocol) disclosed the profile B with the visible sliding sign. The parameters of haemolysis were not elevated. Since the concentration of procalcitonin was low, the infectious origin of disorders was excluded. The elevated values of NT-proBNP at a normal echocardiographic image were considered secondary to lung injury. The results of additional tests were presented in Table 1.

Given the above findings, TRALI was suspected. Symptomatic treatment was implemented; a follow-up X-ray performed after 48 hours showed the regression of changes (Figure 1B).

Anaesthesiol Intensive Ther 2019; 51, 5: 414–416

CORRESPONDING AUTHOR:

Michał Pluta, Studenckie Koło Naukowe przy Klinice Anestezjologii i Intensywnej Terapii, Wydział Lekarski w Katowicach, Śląski Uniwersytet Medyczny w Katowicach, 14 Medyków St., 40-752 Katowice, Poland, e-mail: michal_p2@tlen.pl

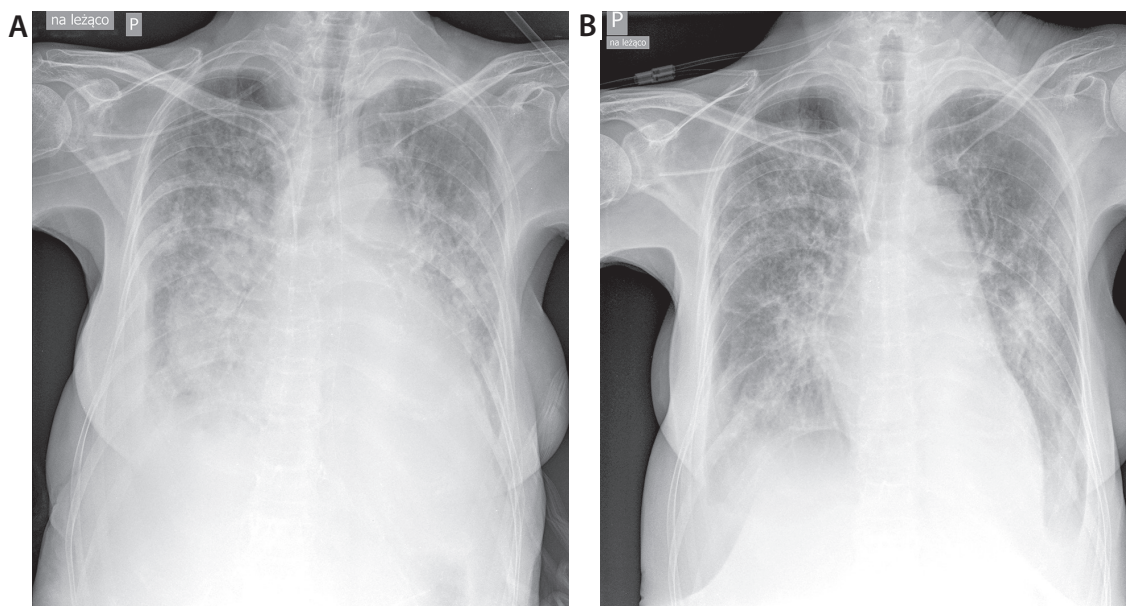


FIGURE 1. A lung X-ray on hospitalization day 2 (A) and 4 (B)

DISCUSSION

The combination of the history taken with clinical experience and the available diagnostic tools, i.e. bedside US (*point-of-care ultrasonography* – POCUS), analysis of critical parameters (*point-of-care testing* – POCT), and laboratory testing allows to determine the most common causes of ARF. In patients receiving blood preparations, post-transfusion complications should, however, always be considered, especially when standard diagnostic methods do not allow to recognise the ARF cause.

TRALI is the most common cause of deaths related blood transfusion [1]. Since specific laboratory tests are not available, TRALI is a diagnosis of exclusion based on the clinical picture and radiological imaging [3]. The injury can develop after the transfusion of any blood preparation, although the majority of cases concern the supply of plasma [4]. The pathogenesis of TRALI is still open to debate and arouses numerous controversies [5].

The ARF symptoms (1) sudden onset, (2) with hypoxaemia (the Horowitz index < 300 and/or $\text{SpO}_2 < 90\%$ with-

out oxygen therapy, and/or other clinical features of hypoxaemia), X-ray-detected bilateral lung oedema, with no evidence of cardiogenic origin of disorders (features of left atrial overload), (3) without other concomitant risk factors of acute lung injury (ALI), (4) and transfusion time frame (up to 6 hours), enables the diagnosis of TRALI. In case of transfusion of larger volume of blood products there is the possibility of the occurrence of a late character TRALI, up to 72 hours from the beginning of transfusion. Implementing the proper treatment, even

TABLE 1. Values of selected laboratory parameters

Parameter	Norm	Hospitalisation day					
		0	1	2*	3	4	5
WBC (G L^{-1})	4–10	11.2	10.8	8.5	11.6	15.2	11.3
RBC (TL^{-1})	4.2–5.7	1.9	2.5	2.9	2.9	2.9	3.1
HCT (%)	37–47	16.9	21.4	25.8	26.2	26.4	27.8
HGB (g L^{-1})	130–160	58	74	87	86	87	90
PLT (G L^{-1})	150–300	74	70	56	59	73	84
Respiratory index		452	408	203	288	260	520
CRP (mg L^{-1})	< 5	98	166	114	63	36	43
Procalcitonin (ng mL^{-1})	0–0.5	–	–	0.34	–	–	–
NT-proBNP (pg mL^{-1})	0–125	–	–	11,642	–	–	–
D-dimers (ng mL^{-1})	< 500	3789	3667	–	–	5106	–

*Diagnosis of TRALI

WBC – white blood count, RBC – red blood count, HCT – hematocrit, HGB – hemoglobin, PLT – platelets, CRP – C-reactive protein

only symptomatic, promotes regression and changes prognosis.

Transfusion-related complications should be reported to the Regional Centre of Blood Donation and Blood Treatment. Whenever another transfusion is needed, leukocyte-poor preparations ought to be ordered.

CONCLUSIONS

Differential diagnosis of ARF in patients receiving blood preparations should consider TRALI, TACO and immunologic haemolytic reaction, irrespective of the history taken. The occurrence of any transfusion-related complication should be reported to the respective blood transfusion services.

ACKNOWLEDGEMENTS

1. Financial support and sponsorship: none.
2. Conflict of interest: none.

REFERENCES

1. Jaworski K, Maślanka K, Kosior DA. Transfusion-related acute lung injury: a dangerous and underdiagnosed noncardiogenic pulmonary edema. *Cardiol J* 2013; 20: 337-344. doi: 10.5603/CJ.2013.0091.
2. Semple JW, Rebetz J, Kapur R. Transfusion-associated circulatory overload and transfusion-related acute lung injury. *Blood* 2019; 133: 1840-1853. doi: 10.1182/blood-2018-10-860809.
3. Kleinman S, Caulfield T, Chan P, et al. Toward an understanding of transfusion-related acute lung injury: statement of a consensus panel. *Transfusion* 2004; 44: 1774-1789.
4. Vlaar AP, Juffermans NP. Transfusion-related acute lung injury: a clinical review. *Lancet* 2013; 382: 984-994. doi: 10.1016/S0140-6736(12)62197-7.
5. Warkentin TE, Greinacher A, Bux J. The transfusion-related acute lung injury controversy: lessons from heparin-induced thrombocytopenia. *Transfusion* 2015; 55: 1128-1134. doi: 10.1111/trf.12994.